

The Use of Orthopedic Wire in Veterinary Surgery

G. Timothy Lee, D.V.M.

Introduction

Flexible stainless steel wire can be one of the most versatile aids in orthopedic surgery either by itself or in conjunction with other implants. When used with intramedullary pins, Kirschner Wire or screws, repairs are possible that would be otherwise very difficult.

Instruments used to apply stainless steel wire can be as simple or as elaborate as the surgeon wishes. For most applications, one needs a method of creating a hole in the bone, a method to twist the wire ends together, and an instrument to cut off the excess wire. The hole in small fragments of bone is best made by the small K-wire vise holding either a .062" or .045" diameter Kirschner wire. For larger bones, and especially very dense bones, one might want to use a pin drill, hand or power operated, to minimize fatigue of the surgeon and injury to the tissue because of prolonged handling and drilling. The wire, once in place, must be tightened and then twisted securely if it is to function properly. Two forceps never adequately substitute for a well designed wire twister. The wire twister, when properly used, will give equal tension to the two ends of the wire so that they twist around each other. If equal tension is not used, one wire will coil itself around the other.

When cutting the wire, one must realize that the twisted wire is double in bulk and strength. The surgeon must use an instrument that will cleanly snip through the wire twist.

Lastly, consider the type and size of wire. Remember that the wire is meant to bind the bone fragments together rather than to suture the fragments. Always use the largest wire possible. Most orthopedic applications for wire require 18, 20, or occasionally 22 gauge wire. Finer gauges simply don't have the strength to be of use in orthopedics. The wire

should be very flexible so that it will handle well and so that it will not be brittle after placement. The term 316LVM is a grade designation for stainless steel that should be sought in all steel implants including wire.

Handle the wire as little as possible before its use. Remember that stainless steel of this type work hardens, that is, becomes stiffer after being bent. The area that is looped or kinked because of mishandling is harder to shape than that portion of the wire that is still relatively straight. Therefore, always form large bends in the wire until it is ready to be finally tightened and twisted.

Techniques


There are three basic types of orthopedic wire techniques. They are full cerclage, hemicerclage, and tension band wiring. Each technique has some characteristics of the other two. They differ mainly in how the bone is held.

Cerclage

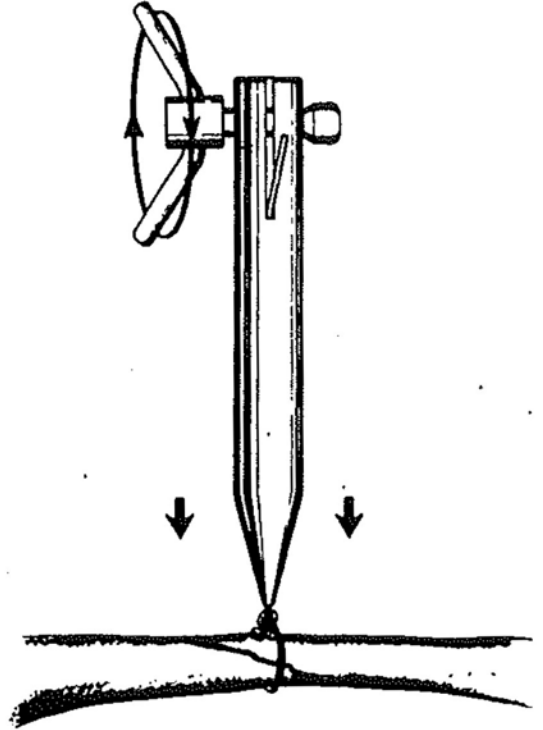
The term, cerclage, indicates that the wire is looped completely around the exterior of the bone and tightened securely to hold two fragments of bone together. A great deal of controversy has existed about completely encircling the bone because it was feared that blood supply would be cut off. Recent studies indicate that such is not the case and that instability rather than cerclage was responsible for failures. An article in the AAHA Journal Nov./Dec. 1977 by Drs. Stephen J. Withrow and David L. Holmberg, describes a series of long bone repairs using cerclage. The fractures described were very long oblique or longitudinal fractures. Most often cerclage is used in conjunction with another technique such as pinning to prevent overriding of oblique fracture fragments or to prevent rotation. Principles of cerclage wiring must be closely

EYELET WIRE TECHNIQUE.....

1. The wire is placed around the bone and is pulled through the eye of the instrument. Then the wire is inserted in the tightener. The handle is removed from the instrument, and the wire is pulled through the hole in the handle.

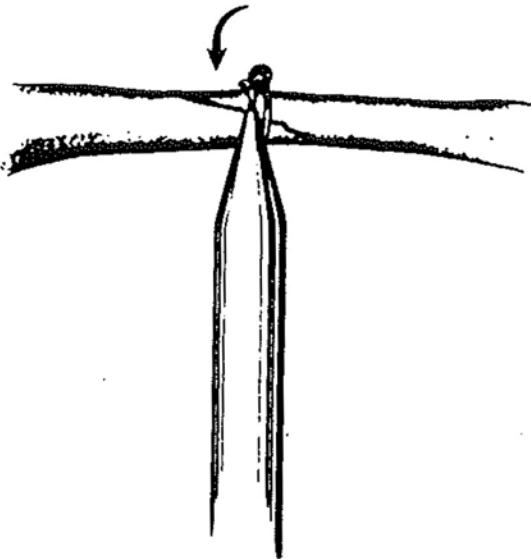


2. The surgeon turns the handle toward the slot in the tightener, so that the end of the wire will move when the handle is turned.

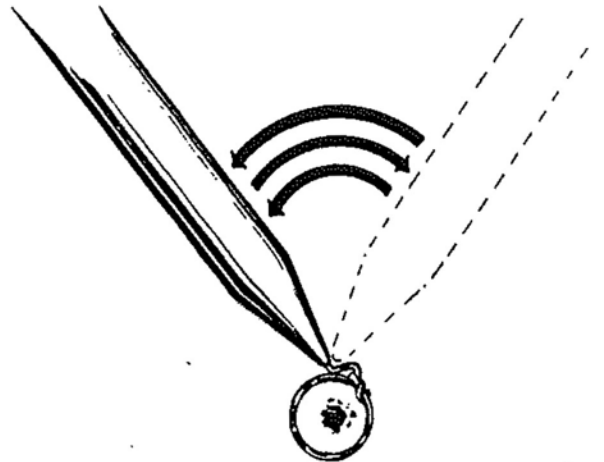


Be sure to hold the tension created and do not release until the wire is bent over the loop, as shown in the next step of the procedure

3. The surgeon then bends the wire sharply in the eye, after which he loosens the tightener.



4. The wire is then cut 1/2 inch (12.7mm) from the "bend." The surgeon may also break the wire by moving the instrument back and forth.



Most surgeons simply cut the wire

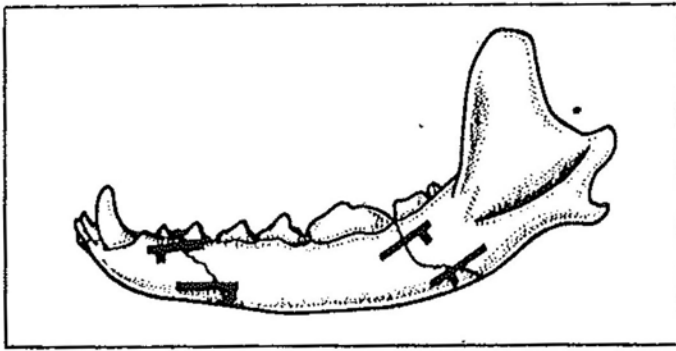


Figure 5

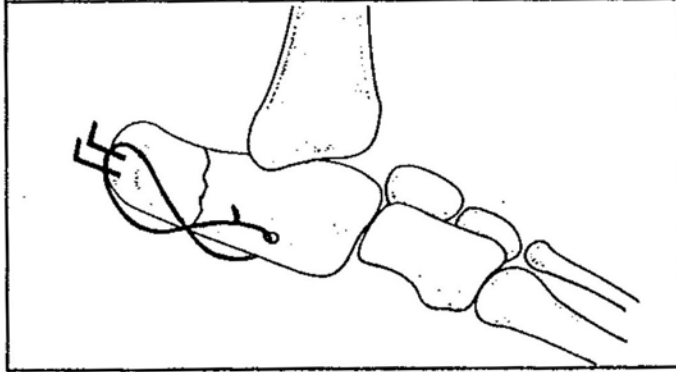


Figure 7

Many of the same precautions apply to this technique that applied to full cerclage.

1. Use only 18 or 20 gauge wire with 22 gauge used in the very small patient.

2. Twist to secure the wire; never knot.

3. Do not include soft tissue.

Application of hemicerclage wire in flat bones consists basically of aligning the fragments, drilling a hole in both fragments well away from the fracture line and placing the wire. Be certain when placing the wire to keep the wire loops as large as possible until ready to tighten the wire so as to prevent kinking. Shape the wire closely to the bone and place the wire twister. Pull away from the bone at right angles and twist until secure. Bend the twisted wire to the bone and cut the excess (See Figure 5).

The major variation to this technique is the placement of pins through the bones prior to hemicerclage. The pin or pins often give strength unavailable with wiring alone. They also tend to prevent folding or hinging at the fracture line.

When using the hemicerclage in long bone fractures, the fracture is pinned or otherwise repaired with the primary implant. The hemicerclage wire is then placed to secure fragments to the larger portions of bone or may be used to stabilize long oblique fractures. The wire may be placed through a single hole drilled through both fragments or through a pair of holes.

Tension band wiring

Tension band wiring is a technique that uses a heavy wire placed across a fracture in such a way as to convert distracting forces into compressive force. Tension band wiring may be used by itself or in conjunction with pins, Kirschner wire, or screws. The wire

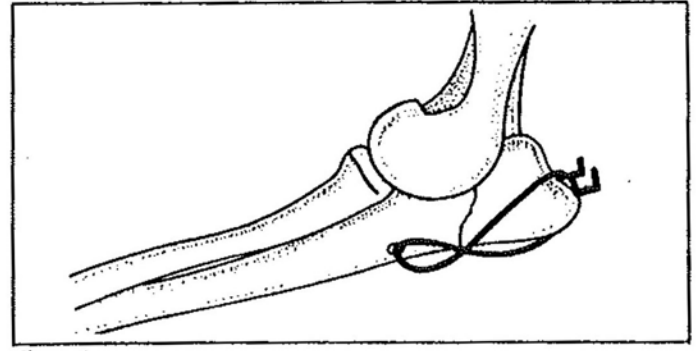


Figure 6

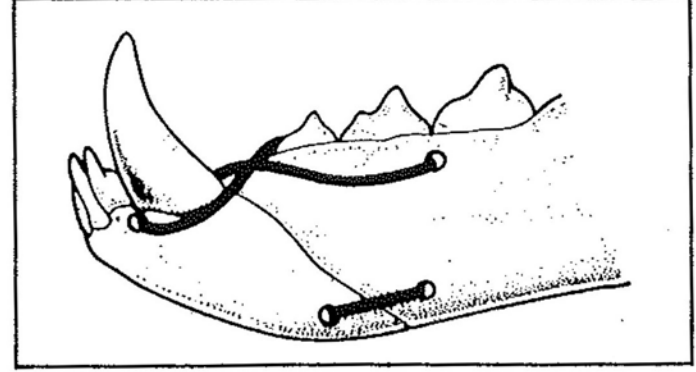


Figure 8

is placed on the tension side of the bone; that is, the side that would open first should bending occur.

An example of tension band wiring is the repair of the olecranon. If the olecranon has been fractured or osteotomized behind the semilunar notch, it is repaired by a pin or screw through the olecranon into the body of the ulna. Since the triceps muscle group attaches to the most caudal portion of the olecranon, an impressive distracting force is trying to pull upon the olecranon and often succeeds in bending or breaking the fixation device. To convert this repair into a tension band wiring, a hole is drilled transversely in the ulna distal to the semilunar notch. A wire is then placed through the hole. The ends of the wire are crossed over the ventral edge of the ulna and one end looped around the end of the pin or screw as it projects beyond the end of the olecranon. The two ends of the wire are then tightened and twisted together with the twist midway between the hole in the ulna and the end of the olecranon. Now when the triceps tries to distract the fracture, that force will instead force the two fragments tighter together.

This technique can be used in similar situations such as:

1. Fracture of the tuber calcis (See Figure 6).
2. Tibial crest avulsion.
3. Patellar fractures.
4. Greater trochanter of the femur - fracture or osteotomy (See Figure 7).
5. Fractures of the mandible just behind the canine (See Figure 8).

Other techniques using wire will occur to the reader. These might include interdental wiring, wire repair of atlanto-axial ligament rupture, and ligament replacement. Wire techniques, when properly used, can be a versatile and rewarding technique.

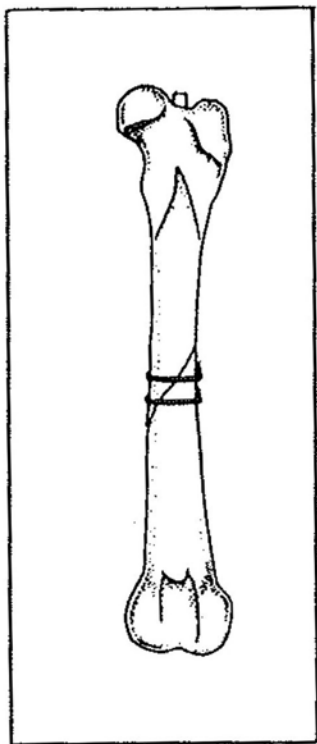


Figure 1

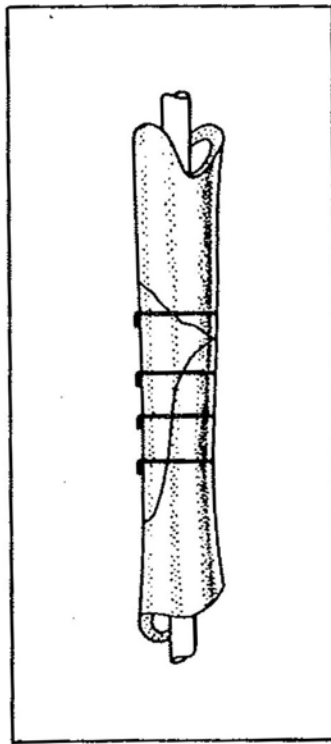


Figure 2

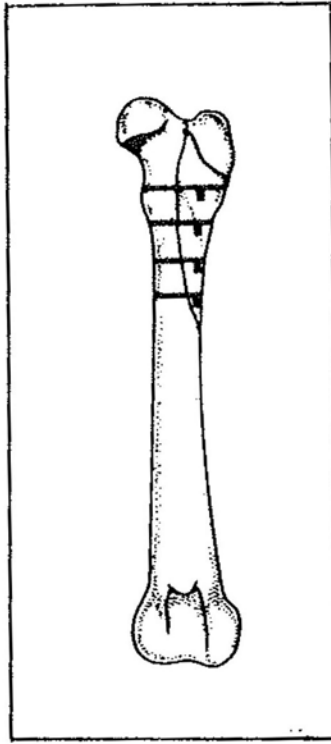


Figure 3

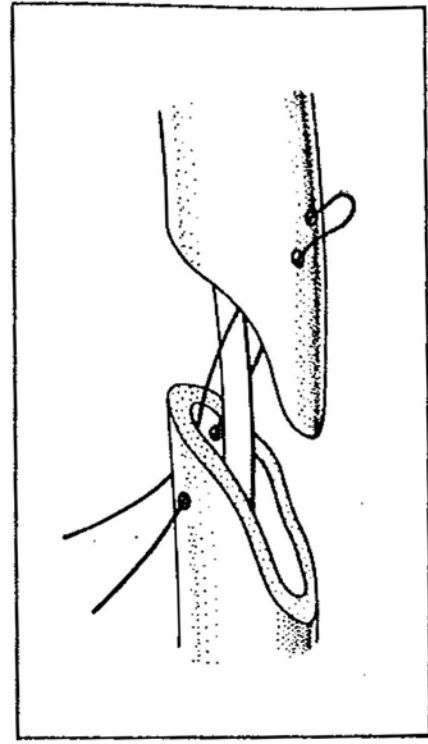


Figure 4

followed for the technique to be successful. First, use only 18 or 20 gauge monofilament wire. Secondly twist to secure, never knot. When using wire of this size, knots are insecure and do not allow adequate tightening of the wire loop. Third, place the wire perpendicularly to the bone making certain not to include any soft tissue structures. Fourth, if wire is placed on tapering bone, notch the bone to prevent slipping. Fifth, in almost all cases, place at least two cerclage wires at 1 cm. intervals.

To properly place a cerclage wire, first remove the wire from the spool so as to straighten the wire as it is removed. For most applications a piece 8 to 10 inches is used. Next, notch the bone to prevent slippage if it is thought to be necessary. Pass the wire around the reduced fragments avoiding all soft tissue. Pull the ends of the wire together and closely shape the wire to the contours of the bone. Attach the wire twister to the wire ends close enough to the bone so that only 8 to 10 twists of the wire will be needed. As you twist the wire, pull firmly away from the bone at right angles to snug the wire around the bone. As maximal tightness is reached, bend the twisted wire down to the bone and cut off the excess. Be certain to position the cut ends so they can not injure nearby vessels or nerves.

In general, one can say the indications for cerclage are:

1. To help stabilize long oblique fractures in conjunction with pinning (See Figure 1).

2. To stabilize large butterfly fragments with pinning (See Figure 2).

3. To repair longitudinal fractures in long bones (See Figure 3).

The contraindications will include:

1. Comminuted fractures.
2. Growing animals.
3. Placement that prevents cortical contact.
4. Overreliance on cerclage to repair fractures.

Most often it is an additional method of stabilization.

Hemicerclage

Hemicerclage means a wiring technique that does not completely encircle the bone. It must pass through a hole in one or both fragments to meet this definition. Examples of this technique include repair of flat bones such as the mandible, maxilla, scapula, and pelvis as well as repair of long bone fractures (See Figure 4). When used in the flat bones it may be used alone or in conjunction with pins. When used in the long bones, it is always an additional technique used with another implant. One exception is binding a small fragment of bone with ligament attached to the larger bone mass.

There are as many patterns for placement of hemicerclage wires as there are inventive surgeons. A review of all of these is beyond the scope of this paper. A large number of the techniques can be found in the "Current Techniques in Small Animal Surgery," published by Lea & Febiger.